

# INNO-EXOMA® EXO-SKIN

Exosome-like cosmetic regenerative complex

BEFORE &  
AFTER CASES

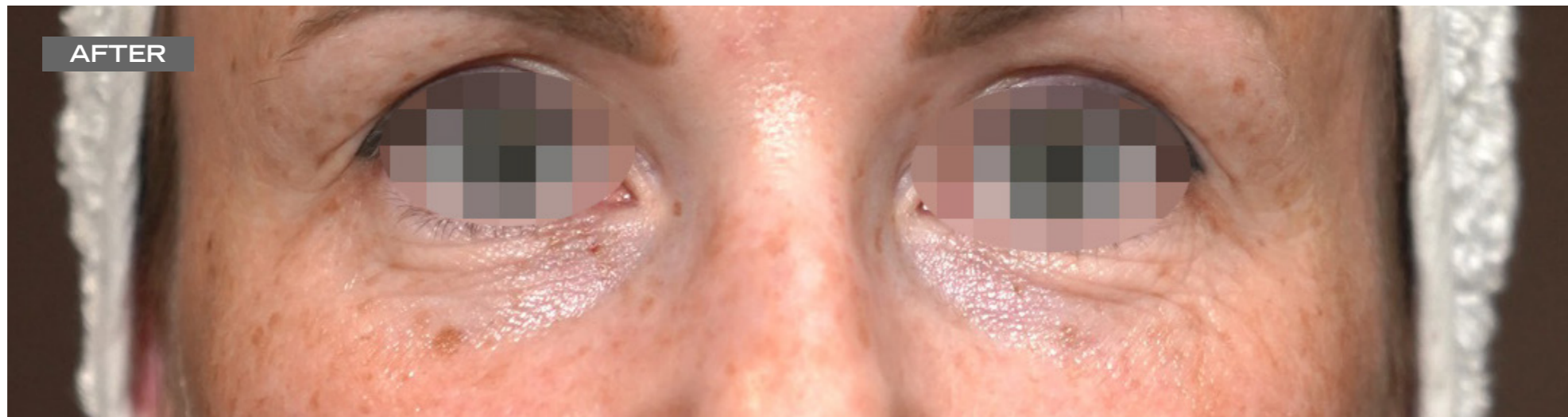
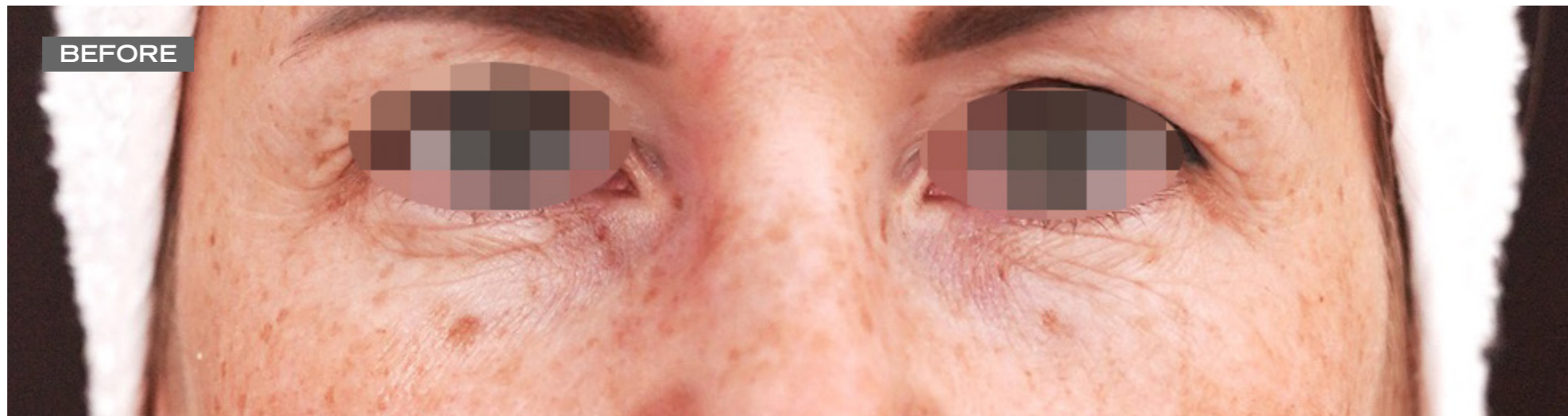


 INNOAESTHETICS

# INNO-EXOMA<sup>®</sup> EXO-SKIN

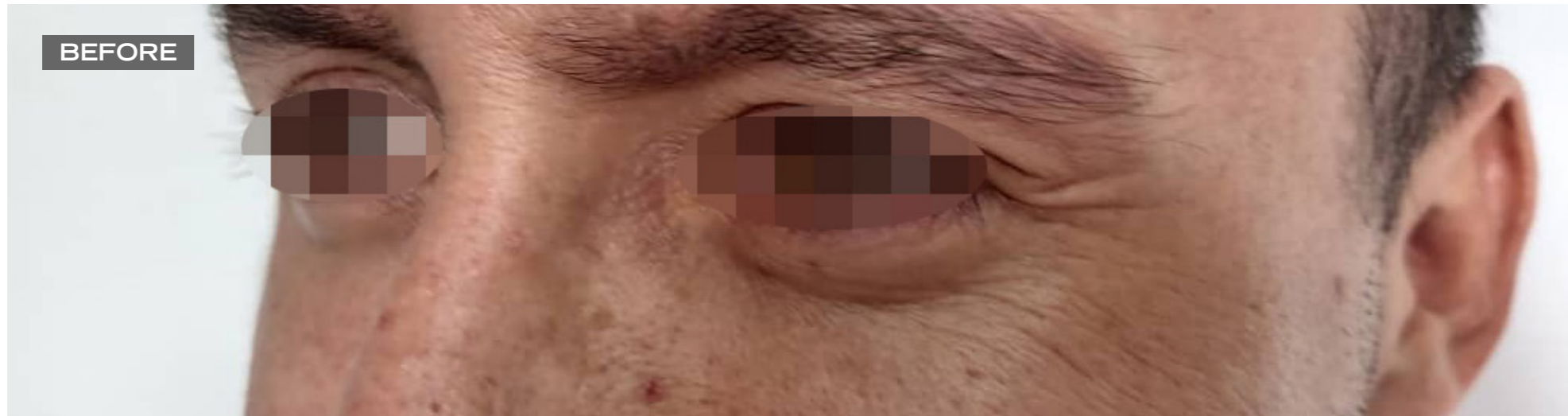Exosome-like cosmetic regenerative complex

Anastasiia Lapshyna, MD  
UKRAINE

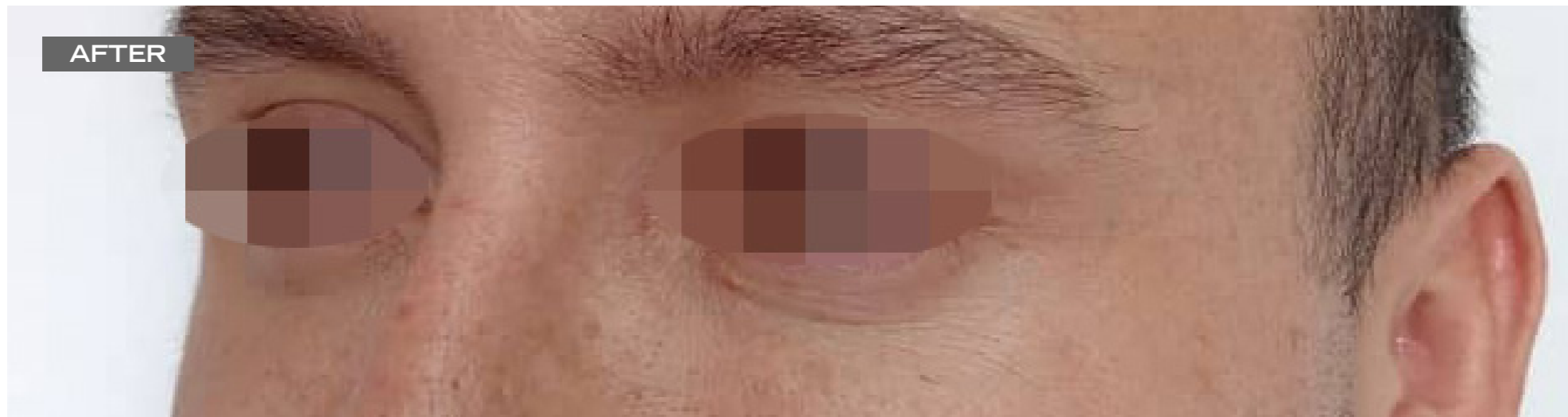


PATIENT CONDITION: Aging in the periocular area and eyelid sagging.  
TREATMENT: 1<sup>o</sup> session of INNO-EXOMA<sup>®</sup> EXO-SKIN with microneedles.  
RESULT: 21 days after the treatment.

Yaisiri Torrealba, MD  
VENEZUELA



BEFORE



AFTER

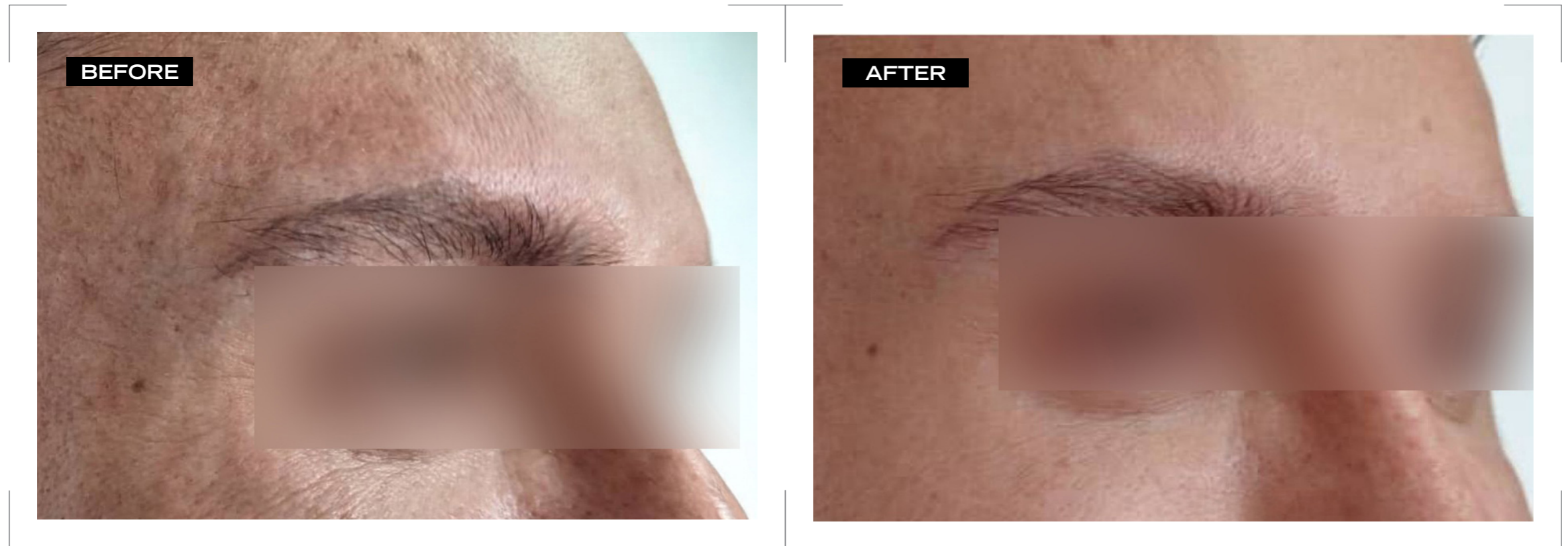**PATIENT CONDITION:** Wrinkles and hyperpigmentation around the eyes and the upper part of the nose.  
**TREATMENT:** 1 session with INNO-EXOMA® EXO-SKIN applied with microneedling.  
**RESULT:** After 15 days.



# INNO-EXOMA<sup>®</sup> EXO-SKIN

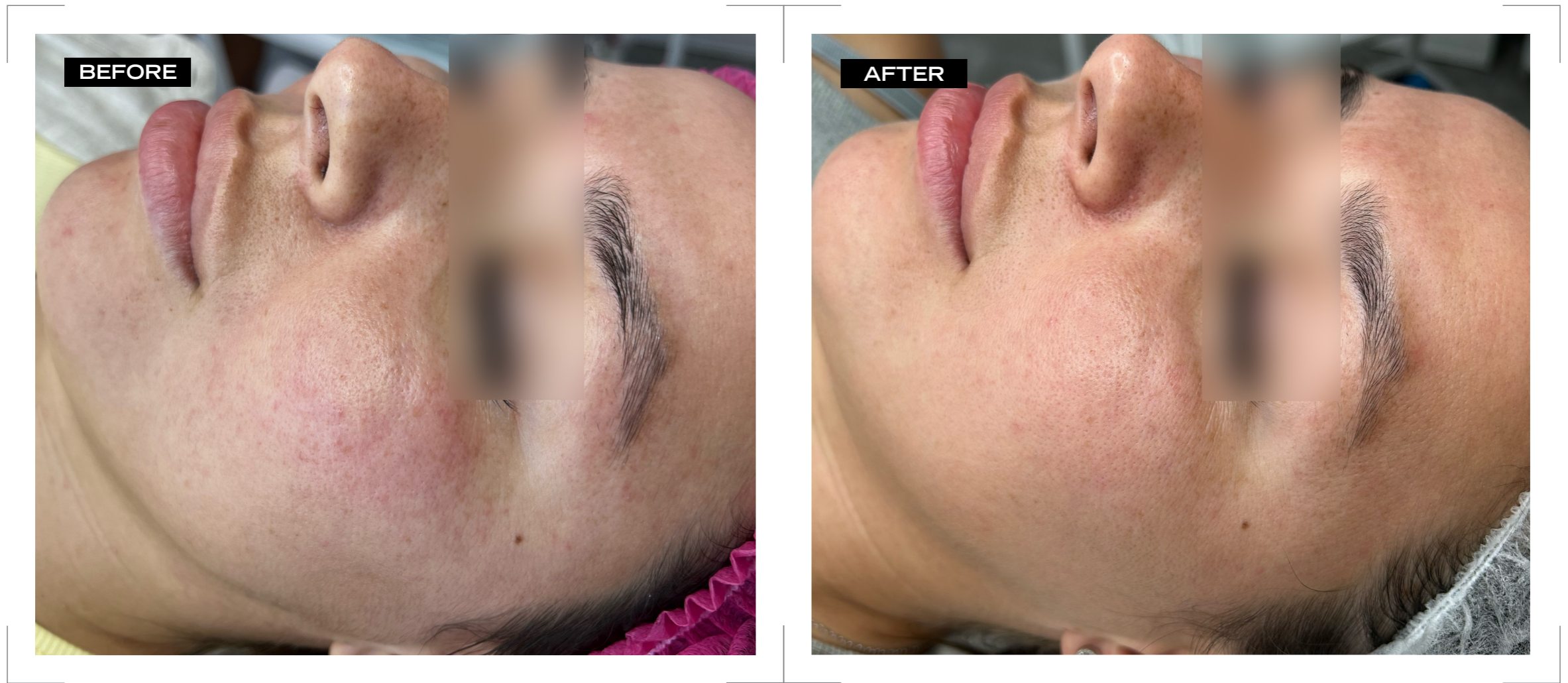Exosome-like cosmetic regenerative complex

Yaisiri Torrealba, MD  
VENEZUELA




**PATIENT CONDITION:** Wrinkles and hyperpigmentation around the eyes and the upper part of the nose.  
**TREATMENT:** 1 session with INNO-EXOMA<sup>®</sup> EXO-SKIN applied with microneedling.  
**RESULT:** After 15 days.

Karina Zagoruyko, MD  
UKRAINE



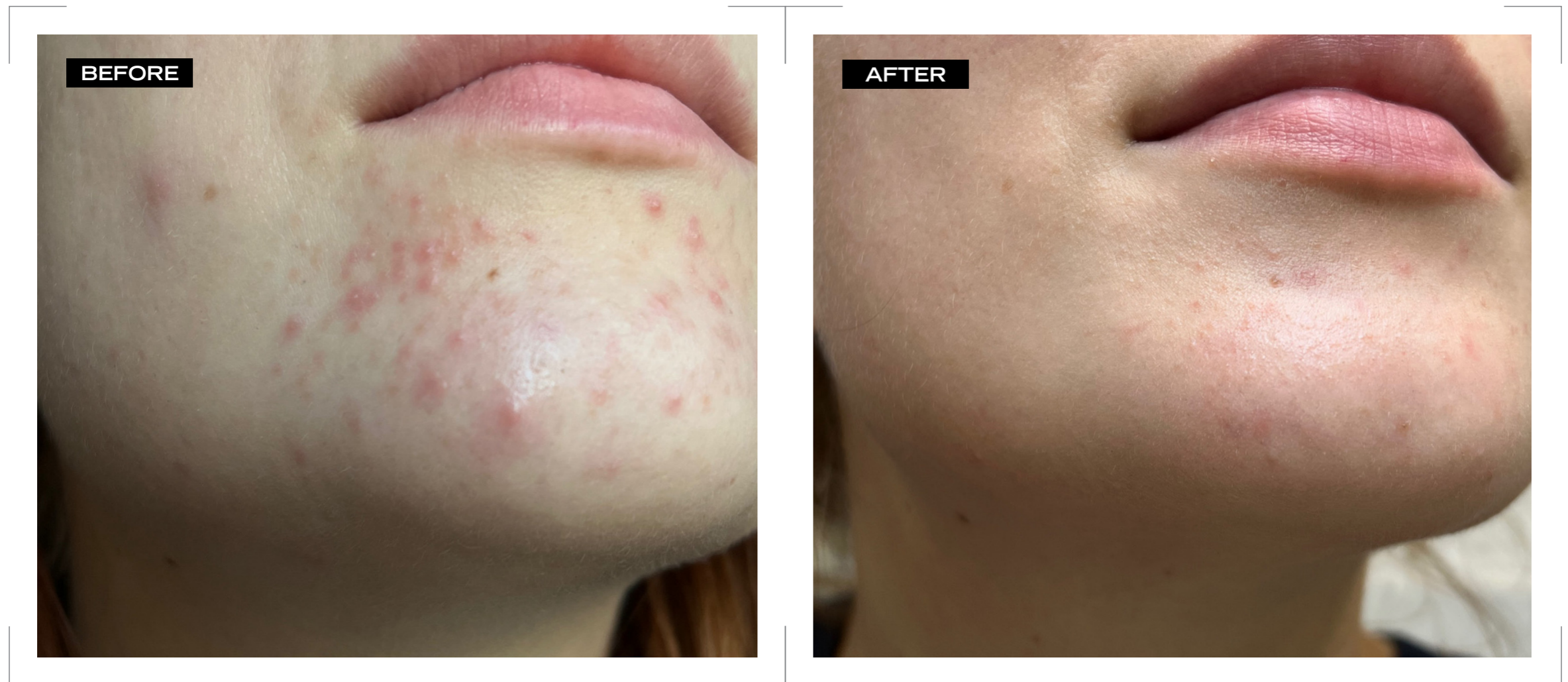**PATIENT CONDITION:** Skin inflammation.  
**TREATMENT:** 1 session de INNO EXOMA EXO-SKIN with Microneedling.  
**RESULT:** 21 days after the treatment.



# INNO-EXOMA<sup>®</sup> EXO-SKIN

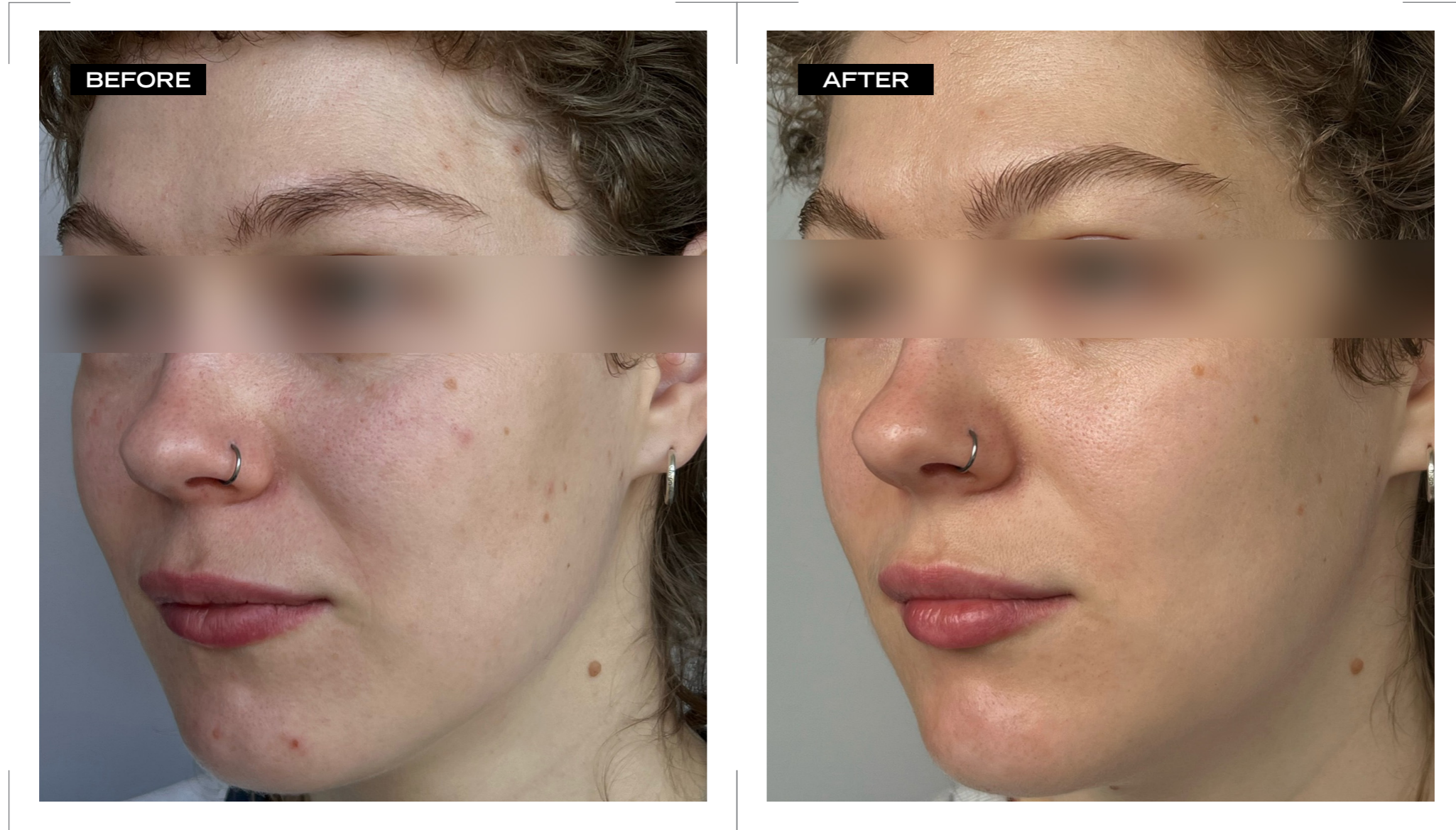Exosome-like cosmetic regenerative complex

Marina Humennaya, MD  
UKRAINE



**PATIENT CONDITION:** Perioral dermatitis after 9 months of therapy with Pimecrolimusum.  
**TREATMENT:** 1 session of INNO-EXOMA<sup>®</sup> EXO-SKIN applied with Micropapules.  
**HOME CARE:** INNO-EPIGEN<sup>®</sup> Antiox Serum only.  
**RESULT:** 45 days after the treatment.

Marina Humennaya, MD  
UKRAINE



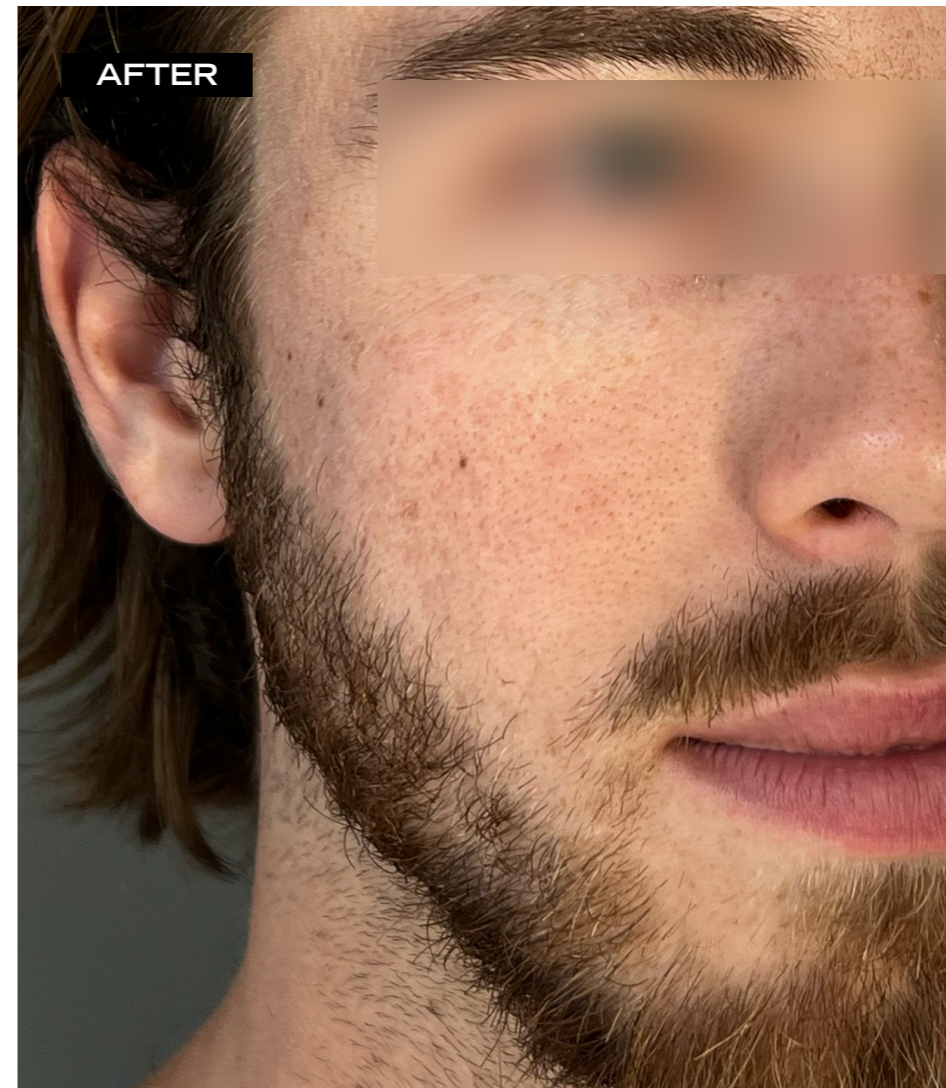
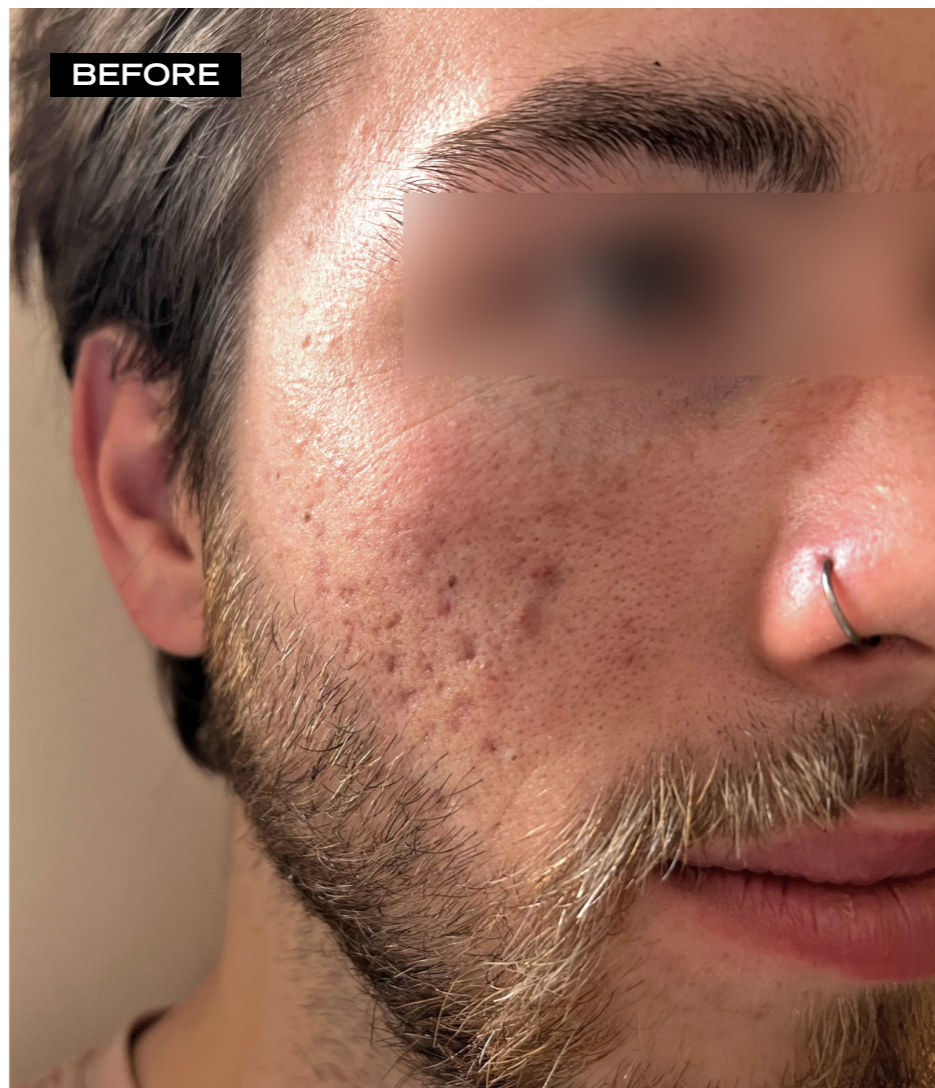**PATIENT CONDITION:** Eczema, post-inflammatory hyperpigmentation, acne, and skin dehydration.  
**TREATMENT:** 1 session of INNO-EXOMA® EXO-SKIN. applied with Micropapules.  
**RESULT:** After 10 days.



# INNO-EXOMA<sup>®</sup> EXO-SKIN

Exosome-like cosmetic regenerative complex

Marina Humennaya, MD  
UKRAINE



**PATIENT CONDITION:** Post-acne scars and photoaging.

**TREATMENT:** Session 1: INNO-EXOMA<sup>®</sup> EXO-SKIN applied with micropapules.

Session 2: After 5 days, INNO-EXFO<sup>®</sup> Lightening (45 minutes exposure).

Session 3: After 28 days, Biorevitalization with INNO-CE<sup>®</sup> BI-DENS.

**RESULT:** 28 days after the combined therapy.

Marina Humennaya, MD  
UKRAINE



**PATIENT CONDITION:** Melasma.

**TREATMENT:** 1 session of INNO-EXOMA® EXO-SKIN mixed with ME LINE® ID (2 ml in one syringe), applied with micropapules.

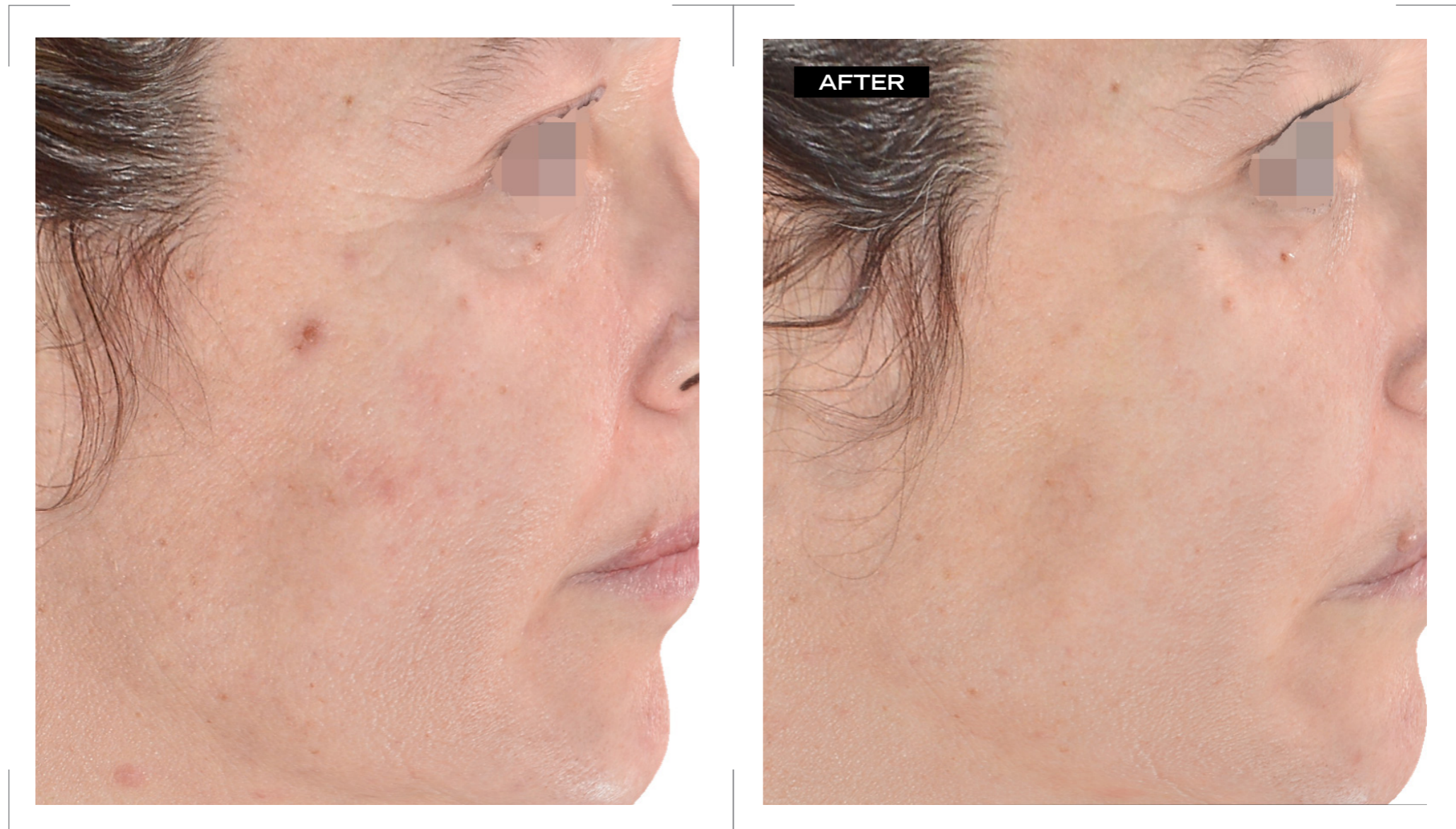**HOME CARE:** SPF and O2 Caucasian Night (3 times a week) during the active solar season (June to September).

**RESULT:** 75 days after the treatment.

# INNO-EXOMA<sup>®</sup> EXO-SKIN

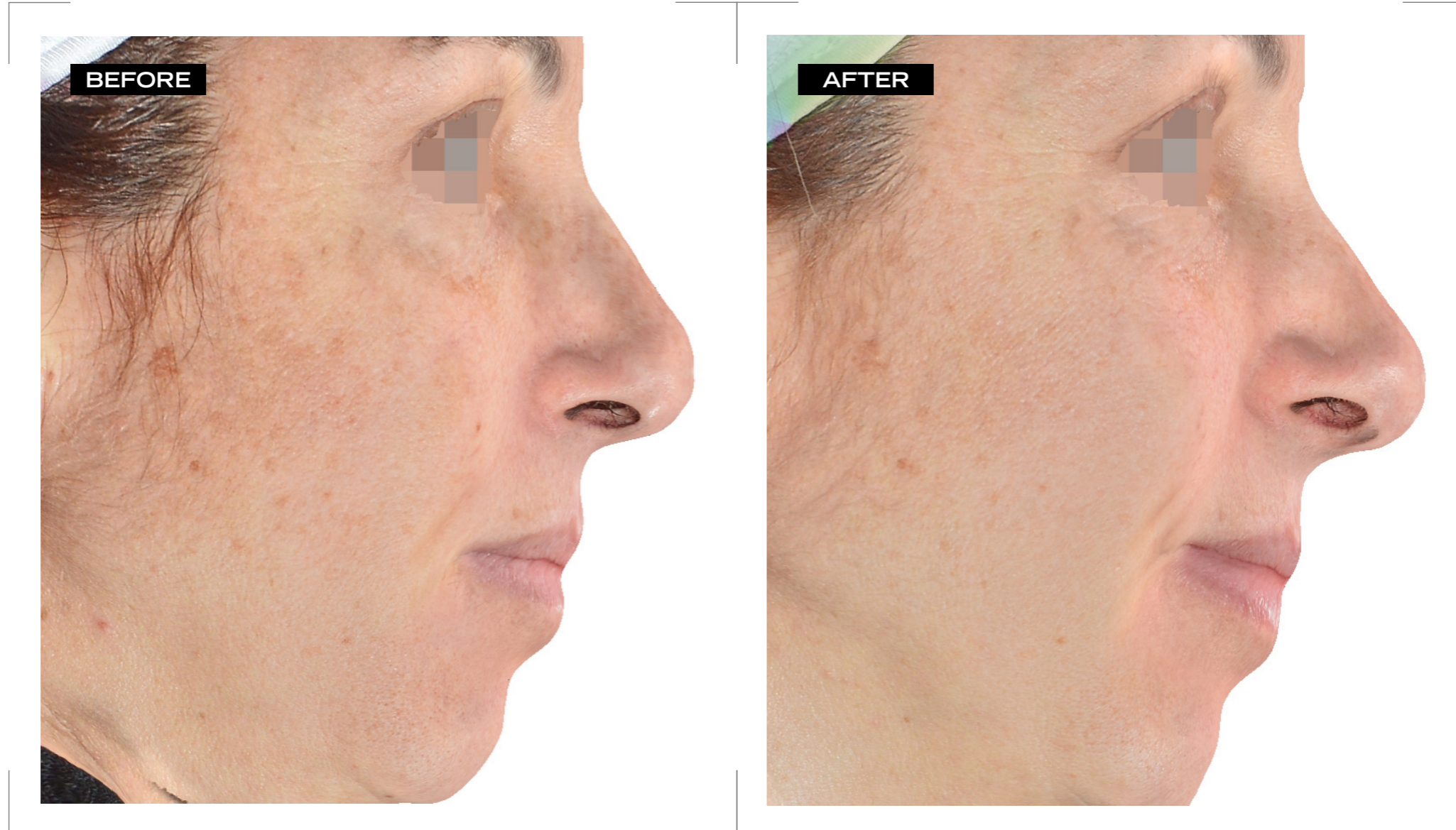Exosome-like cosmetic regenerative complex

Victor Garcia, MD  
SPAIN



**PATIENT CONDITION:** Hyperpigmentation and loss of skin tone.  
**TREATMENT:** 3 sessions of INNO-EXOMA<sup>®</sup> EXO-SKIN with microneedling.  
**INTERVALS:** 21 days between sessions.  
**RESULT:** 70 days after the first session.

Victor Garcia, MD  
SPAIN



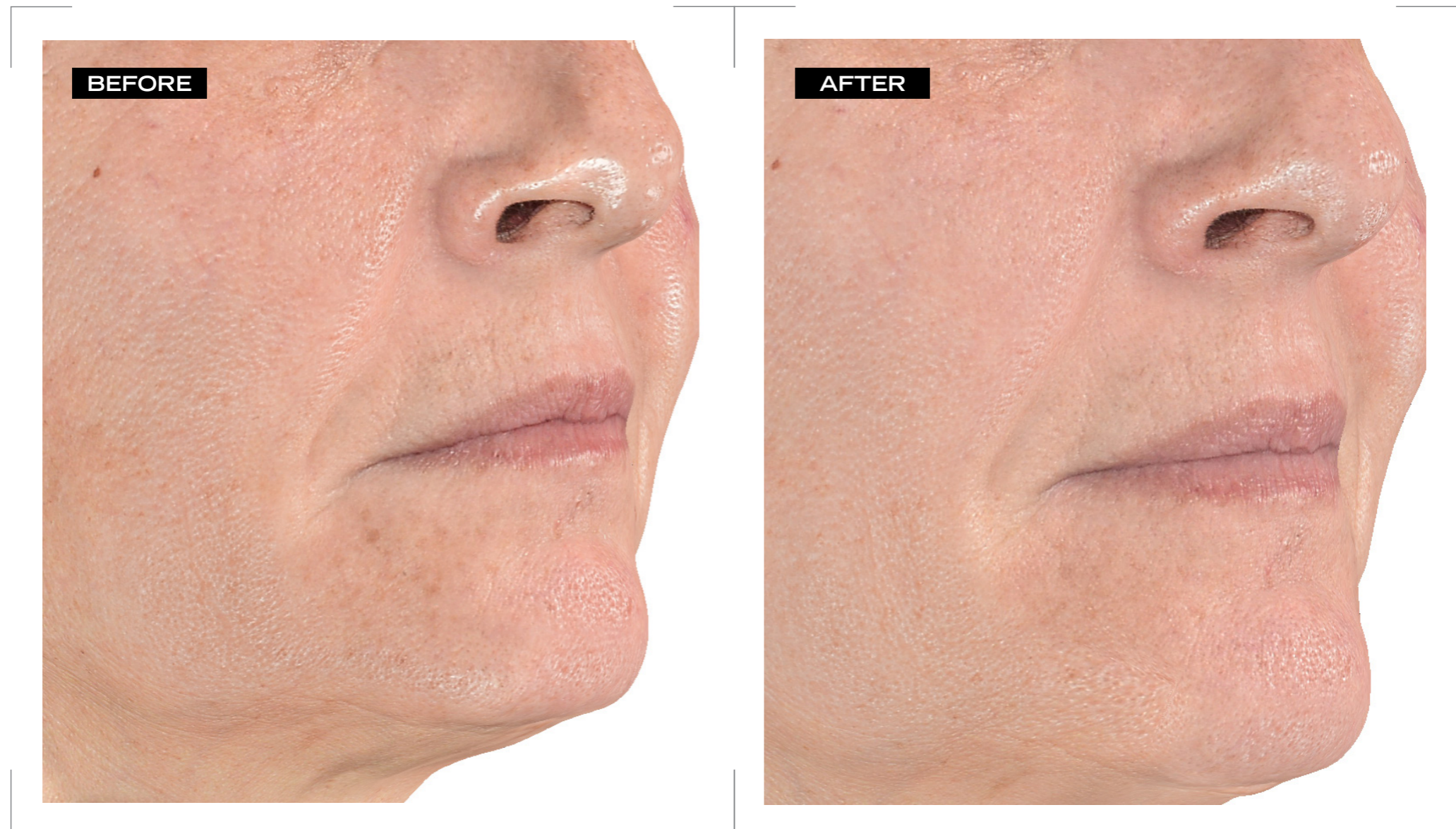PATIENT CONDITION: Hiperpigmentation  
TREATMENT: 3 sessions of INNO-EXOMA® EXO-SKIN with microneedling.  
INTERVALS: 21 days between sessions.  
RESULT: 70 days after the first session.



# INNO-EXOMA<sup>®</sup> EXO-SKIN

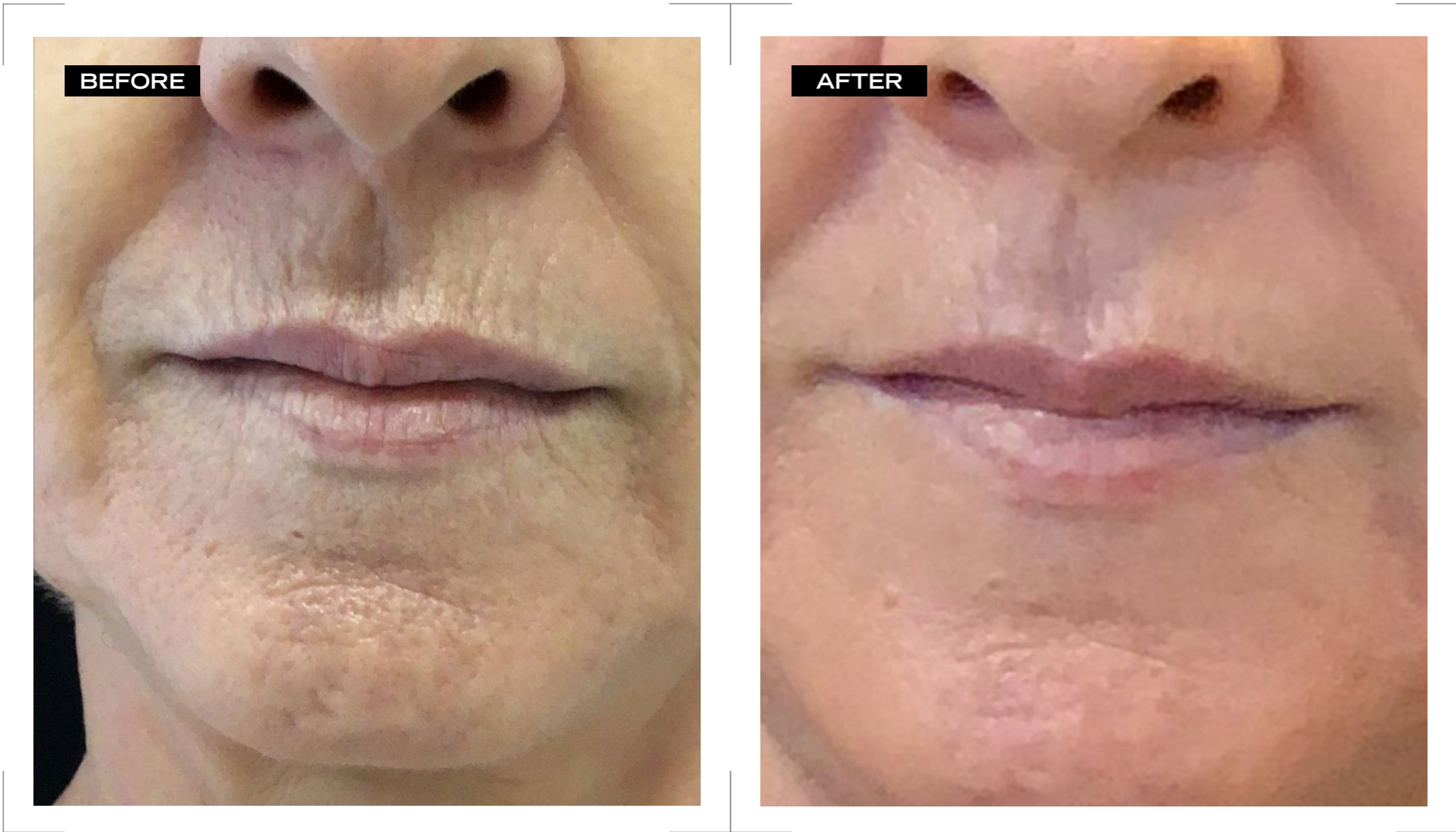Exosome-like cosmetic regenerative complex

Victor Garcia, MD  
SPAIN



**PATIENT CONDITION:** Skin aging, sagging, and expression lines.  
**TREATMENT:** 3 sessions of INNO-EXOMA<sup>®</sup> EXO-SKIN with microneedling.  
**INTERVALS:** 21 days between sessions.  
**RESULT:** 70 days after the first session.

SPAIN



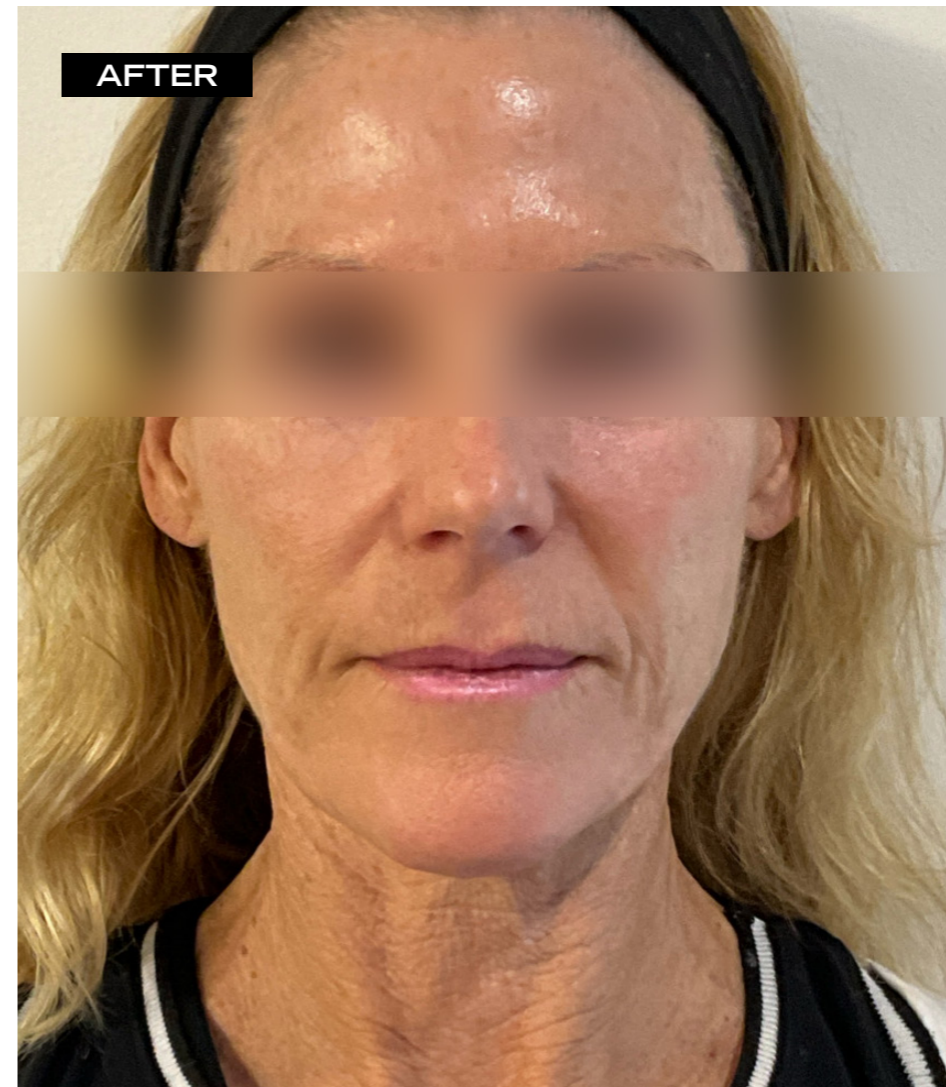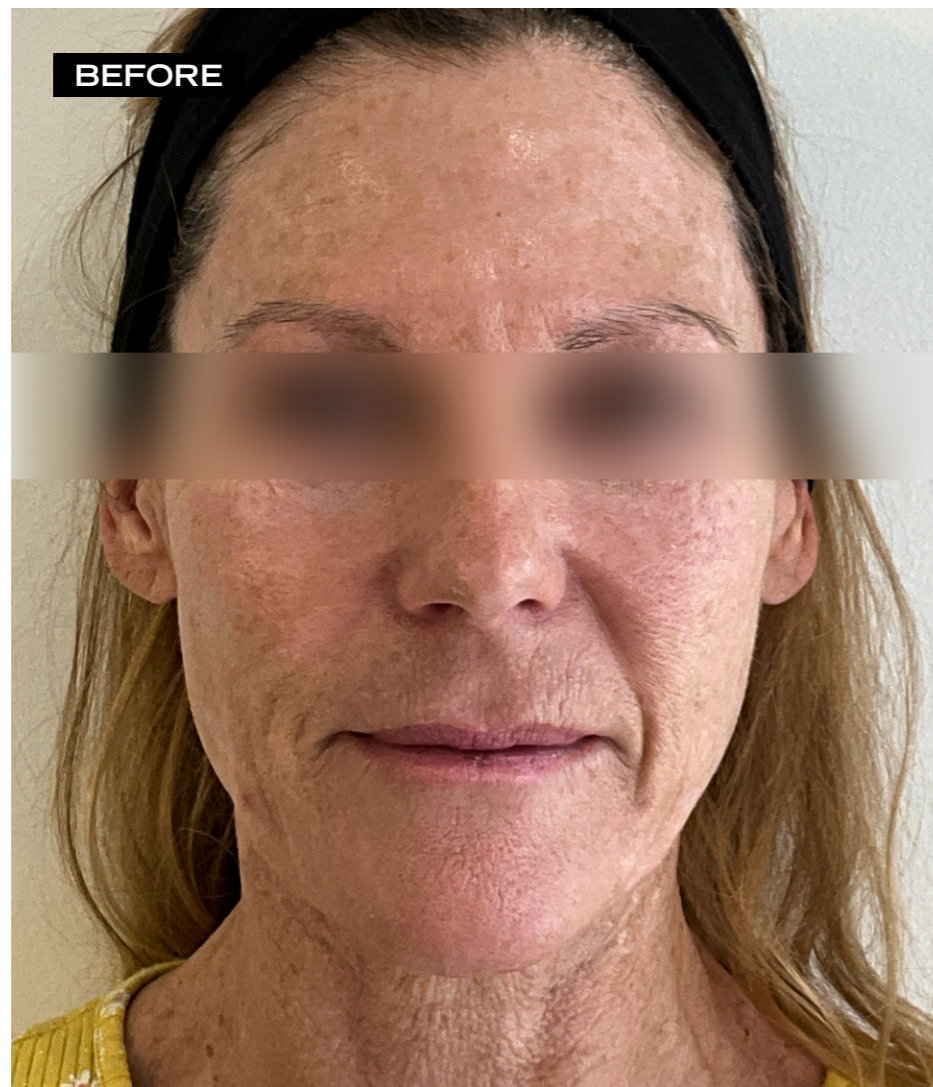**PATIENT CONDITION:** Skin aging, sagging, and expression lines.  
**TREATMENT:** 3 sessions of INNO-EXOMA® EXO-SKIN with microneedling.  
**INTERVALS:** 21 days between sessions.  
**RESULT:** 70 days after the first session.



# INNO-EXOMA<sup>®</sup> EXO-SKIN

Exosome-like cosmetic regenerative complex

Christine Hames, Nurse  
NEW ZEALAND

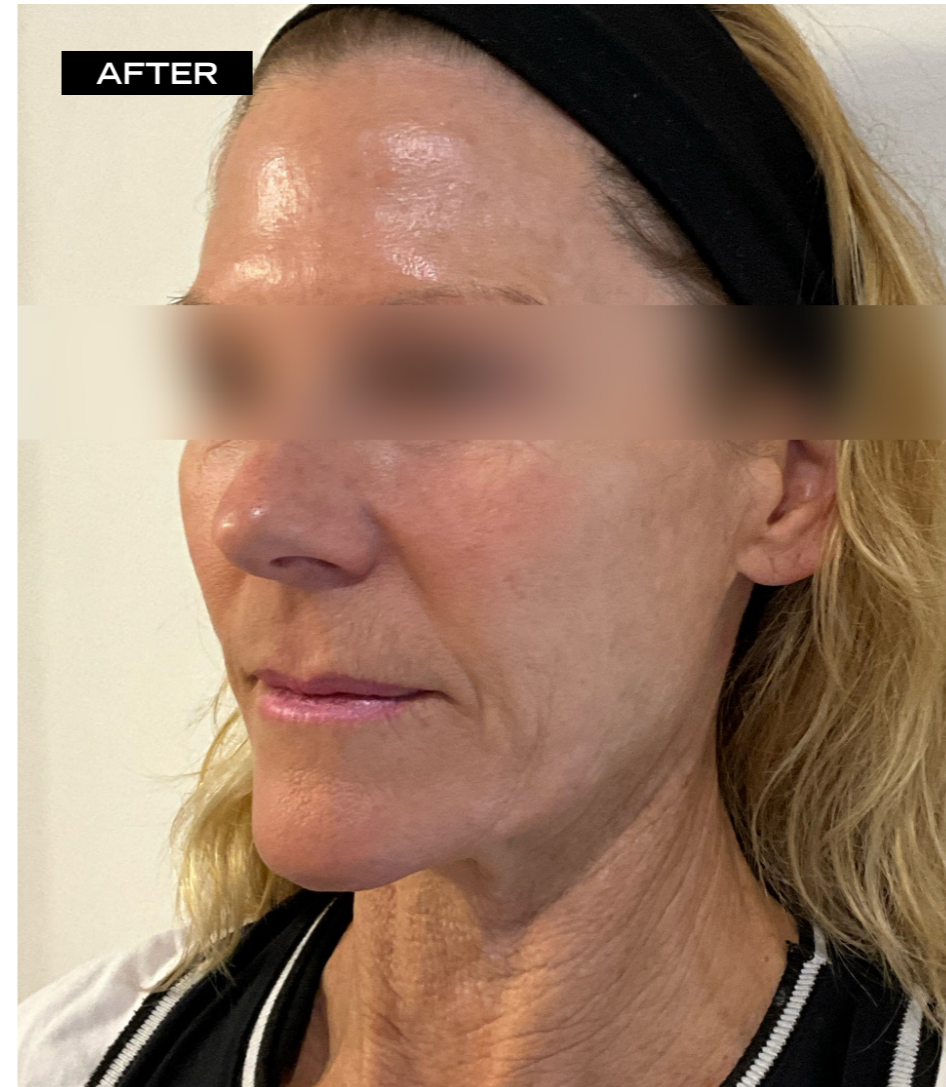
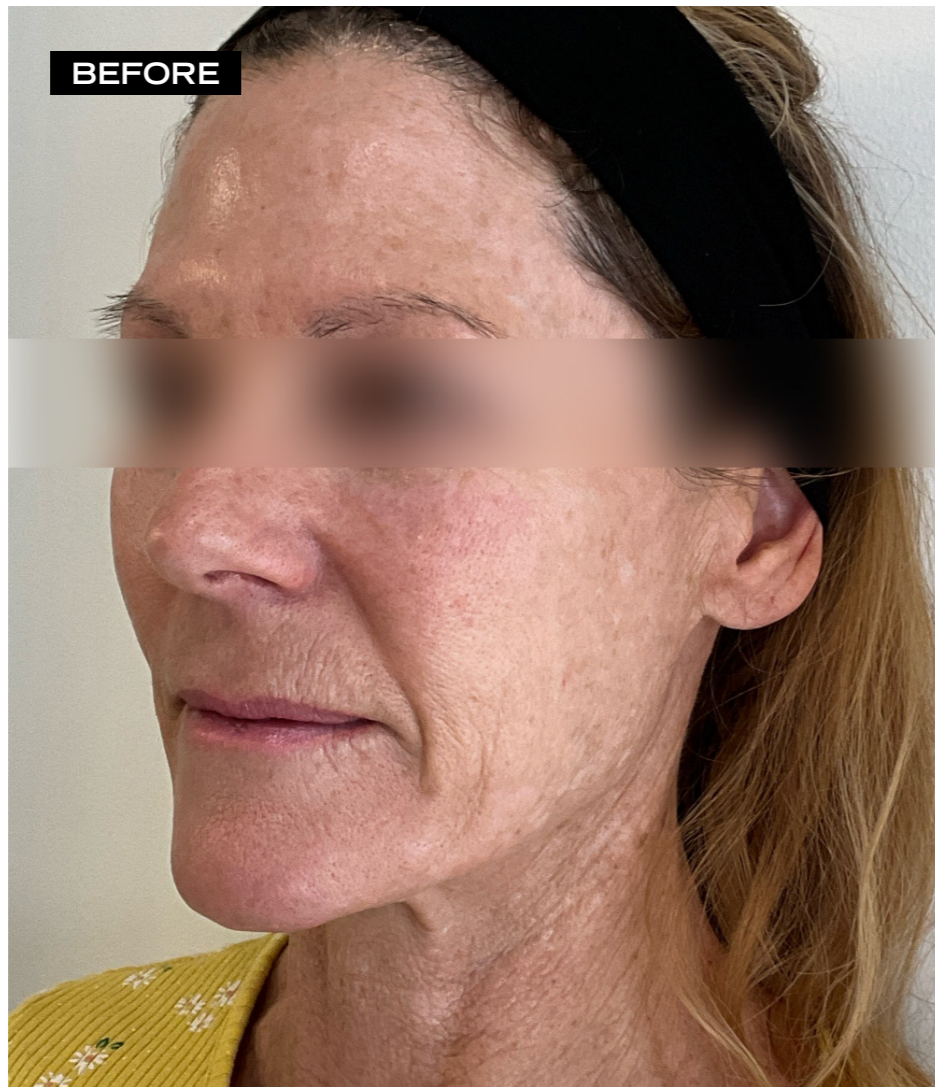
**PATIENT CONDITION:** Aging and pigmentation of the face.

**TREATMENT:** INNO-EXOMO<sup>®</sup> EXO-SKIN applied with RM Star Radio Frequency microneedling, 3 sessions, at 21-day interval.

**RESULT:** After the third session.

Christine Hames, Nurse  
NEW ZEALAND



**PATIENT CONDITION:** Aging and pigmentation of the face.

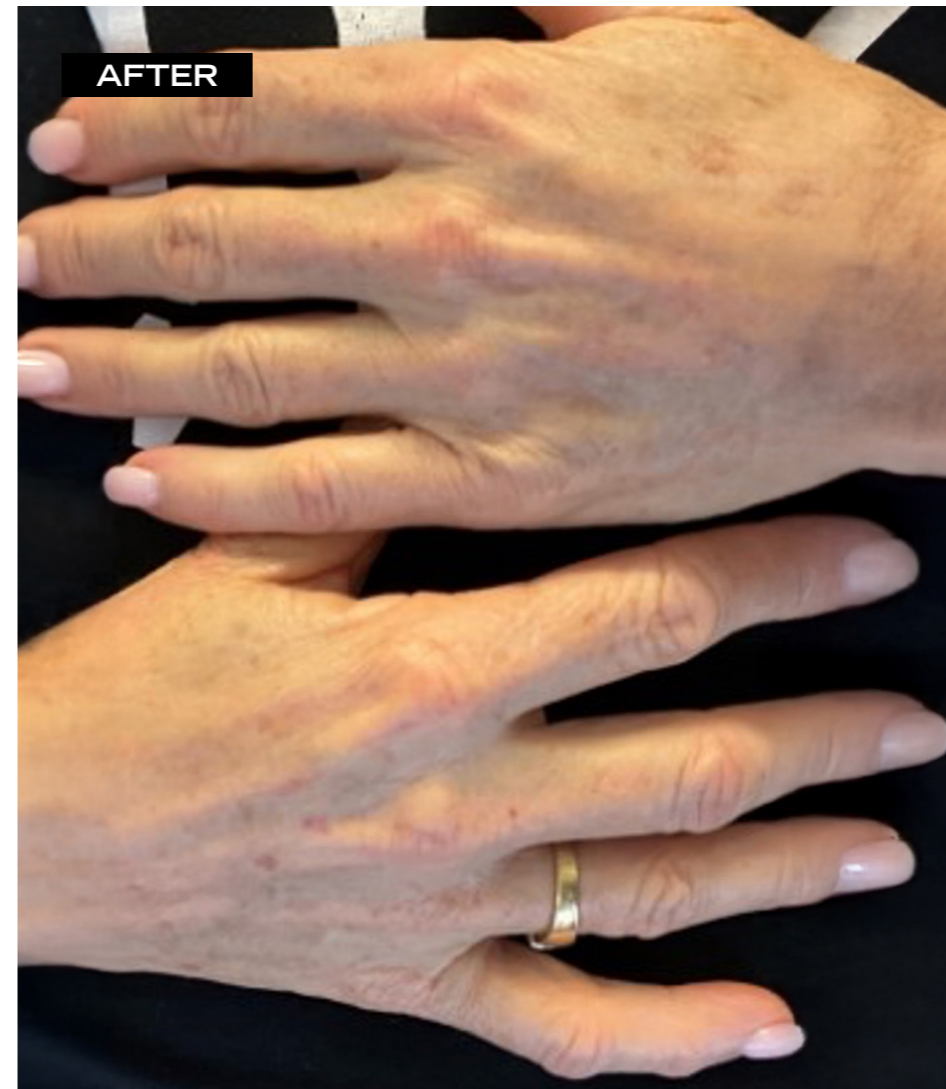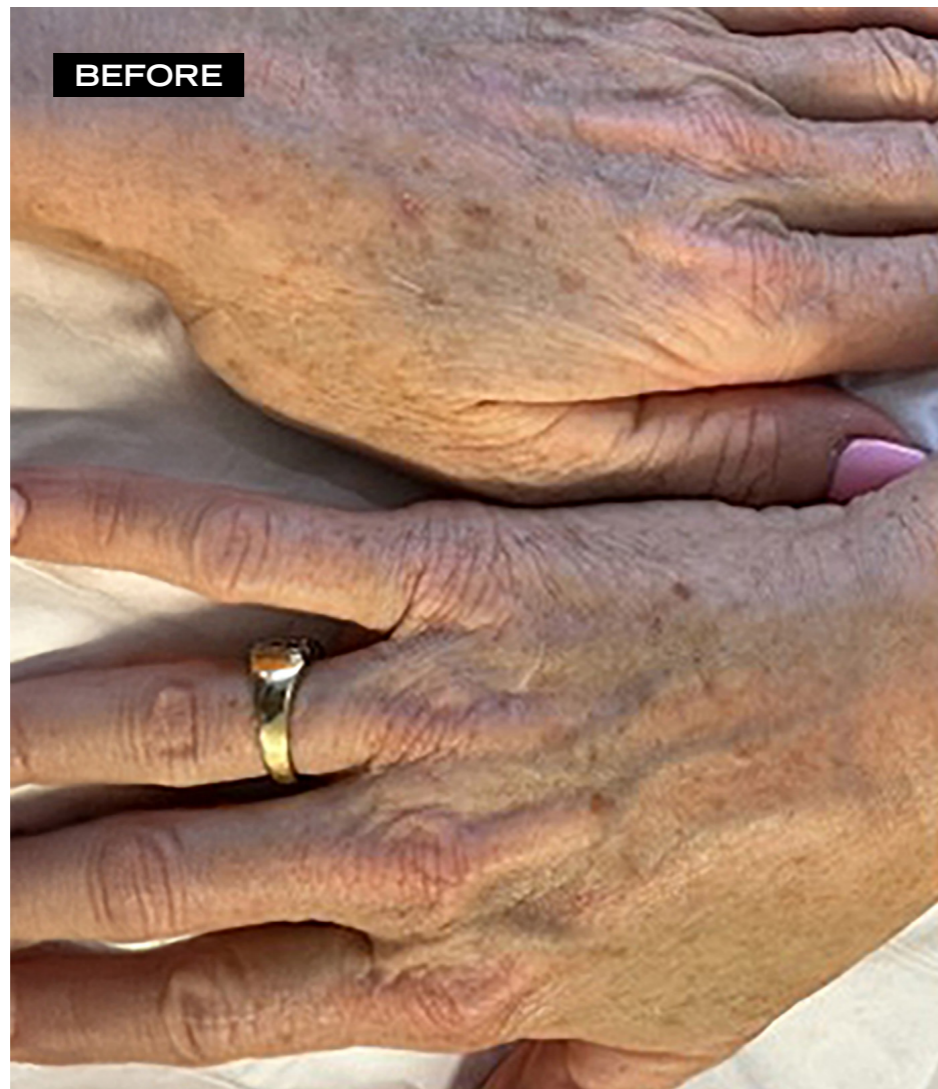
**TREATMENT:** INNO-EXOMO® EXO-SKIN applied with RM Star Radio Frequency microneedling, 3 sessions, at 21-day interval.

**RESULT:** After the third session.

# INNO-EXOMA<sup>®</sup> EXO-SKIN

Exosome-like cosmetic regenerative complex

Christine Hames, Nurse  
NEW ZEALAND

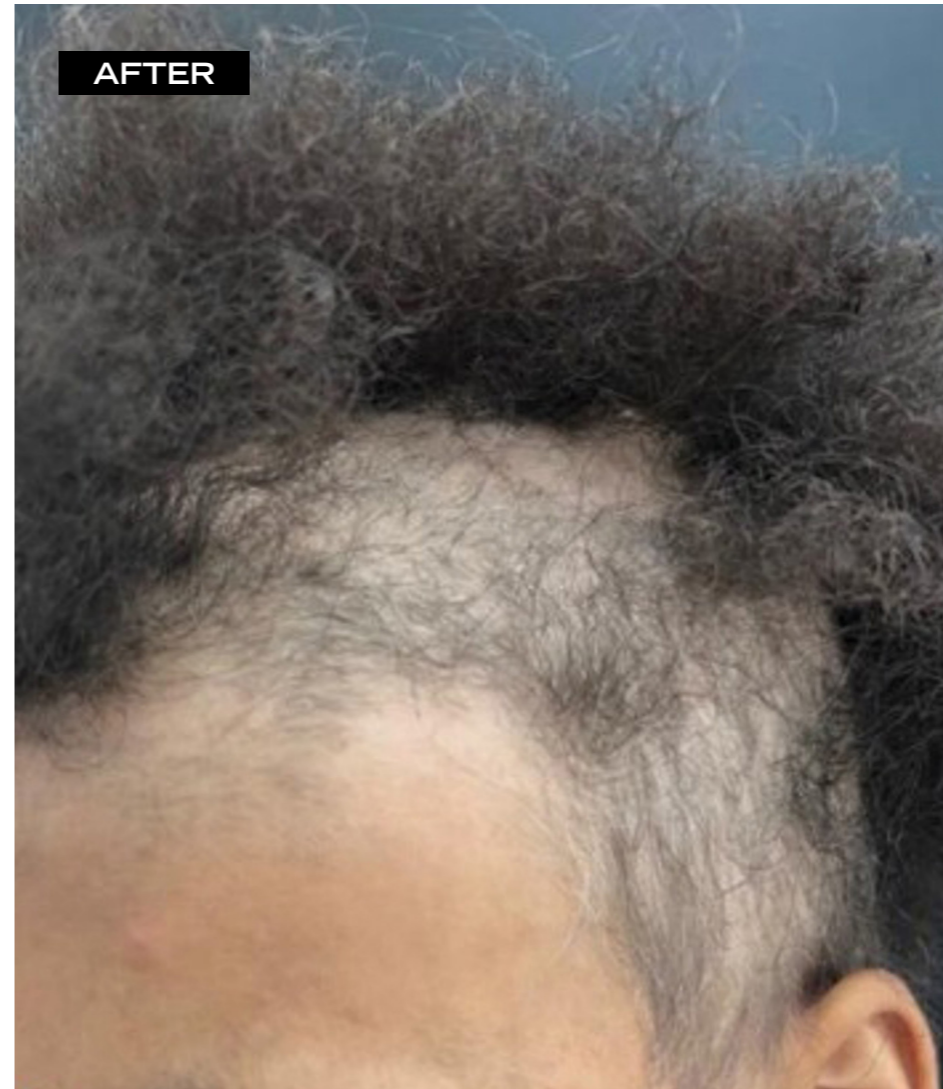
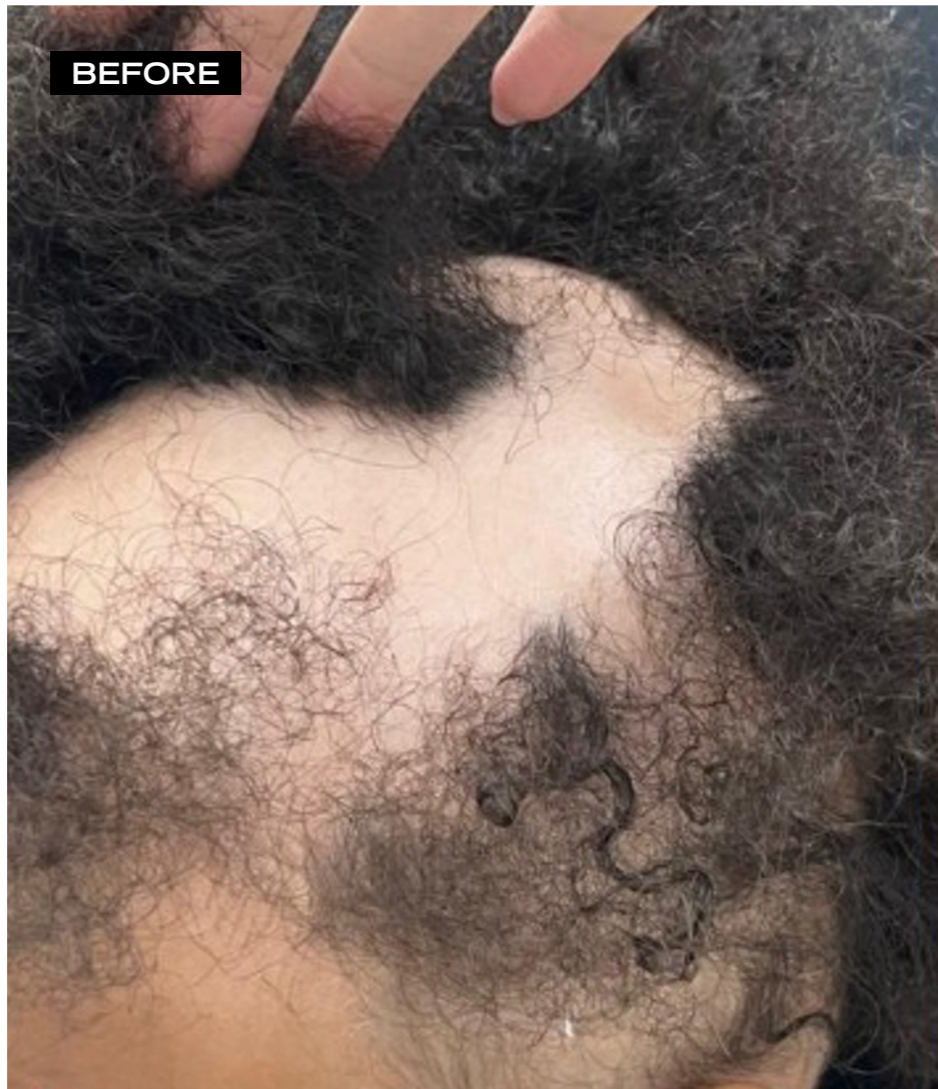


**PATIENT CONDITION:** Aging and pigmentation of the hands.

**TREATMENT:** INNO-EXOMO<sup>®</sup> EXO-SKIN applied with RM Star Radio Frequency microneedling, 3 sessions, at 21-day interval.

**RESULT:** After the third session.

Julia Peres, MD  
BRAZIL



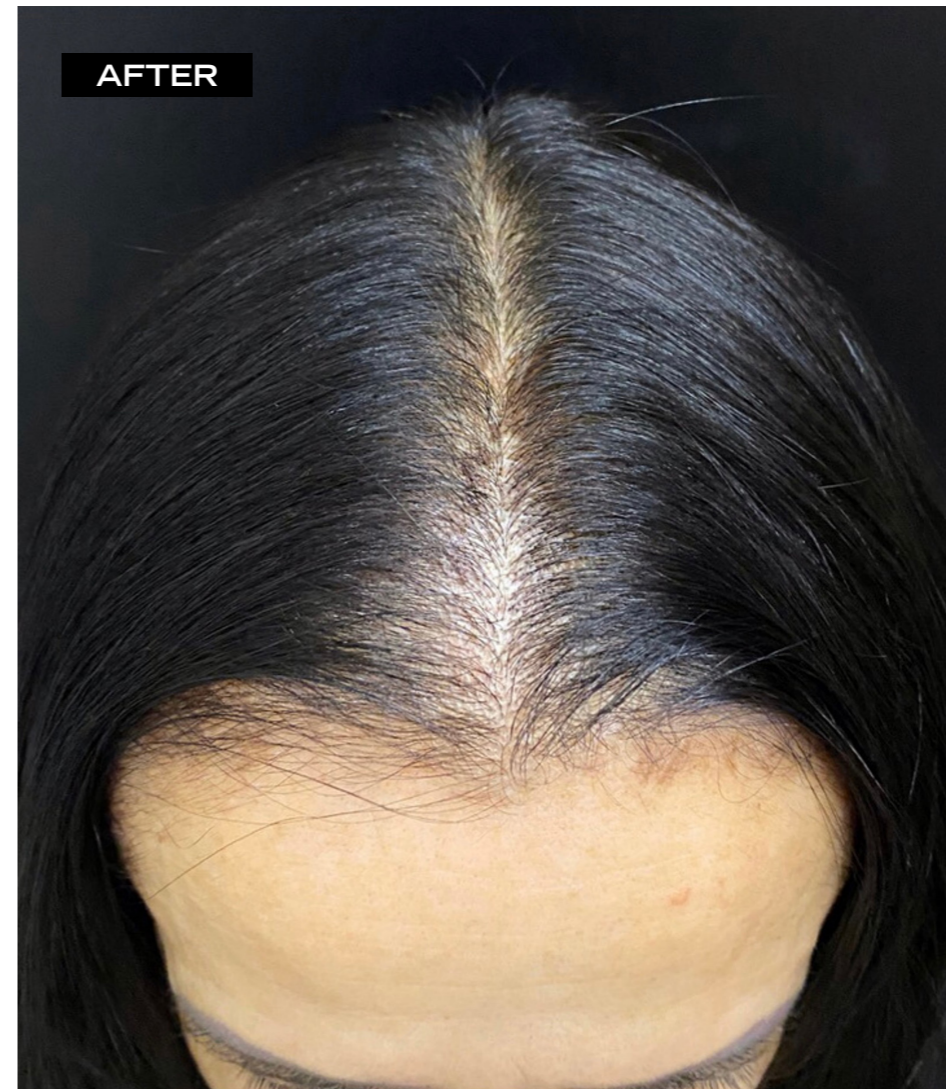
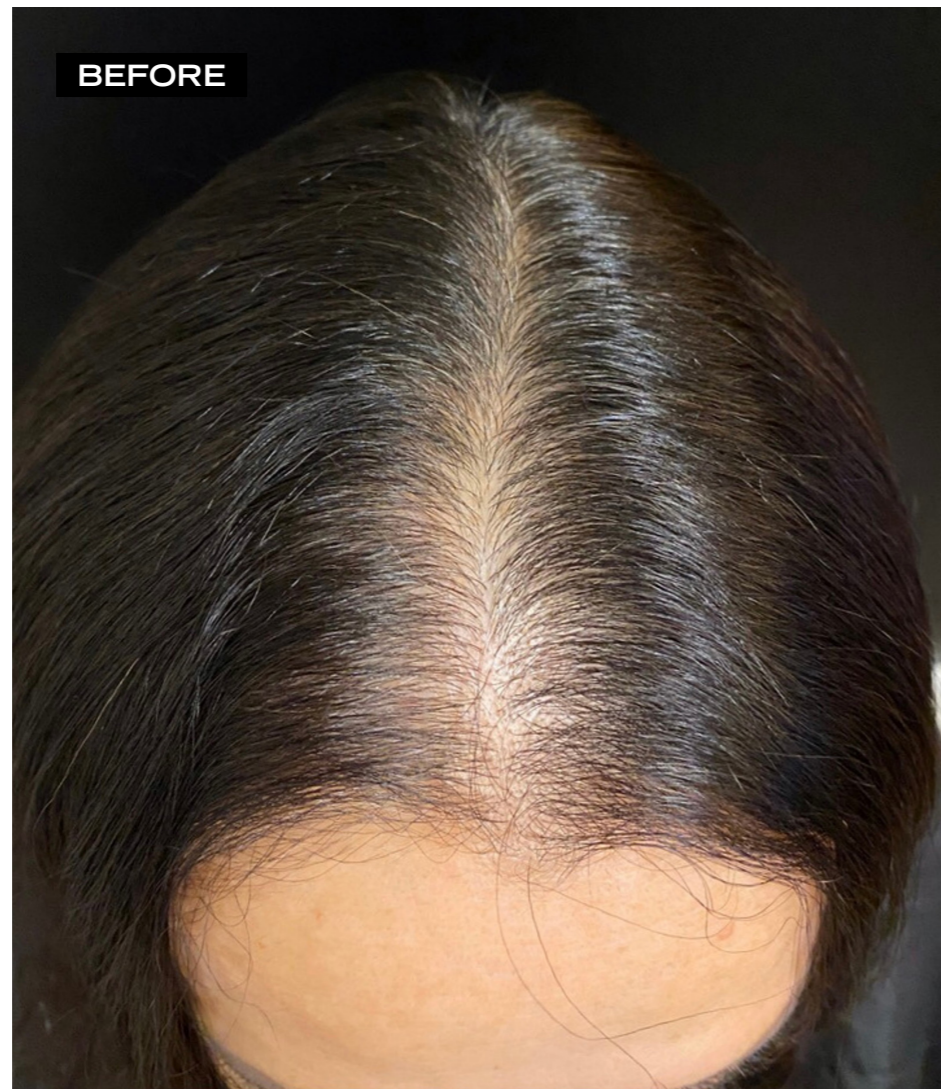
**PATIENT CONDITION:** Alopecia areata infantil.  
**TREATMENT:** INNO-EXOMA® EXO-SKIN applied with Dermapen. 3 sessions with 14–20-day intervals.  
**RESULT:** After the second session.



# INNO-EXOMA<sup>®</sup> EXO-SKIN

Exosome-like cosmetic regenerative complex

BRAZIL

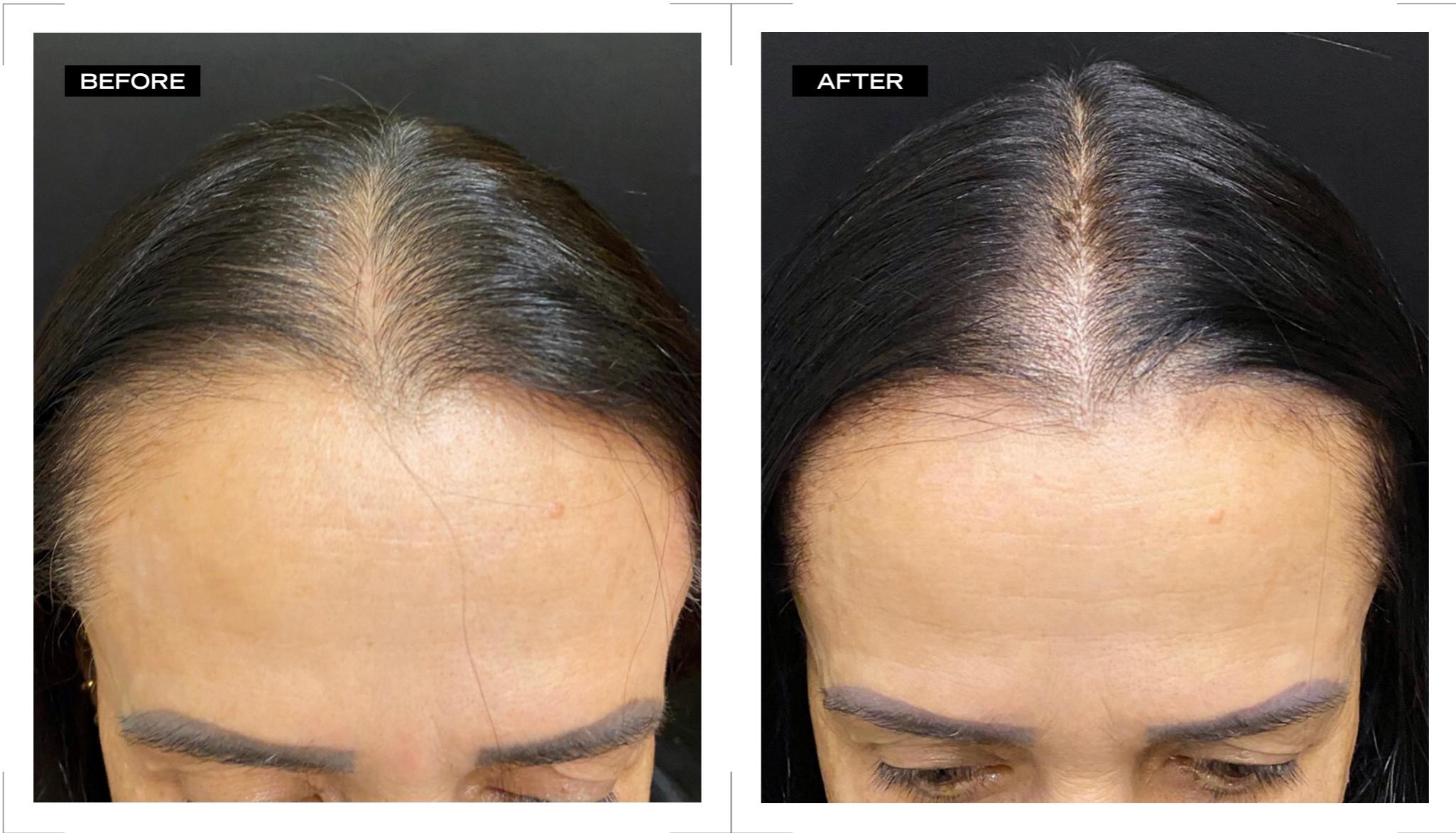

**PATIENT CONDITION:** Female alopecia.

**TREATMENT:** INNO-EXOMO<sup>®</sup> EXO-SKIN applied with mesotherapy. 3 sessions, at 21-day intervals.

**RESULT:** After the third session.

BRAZIL

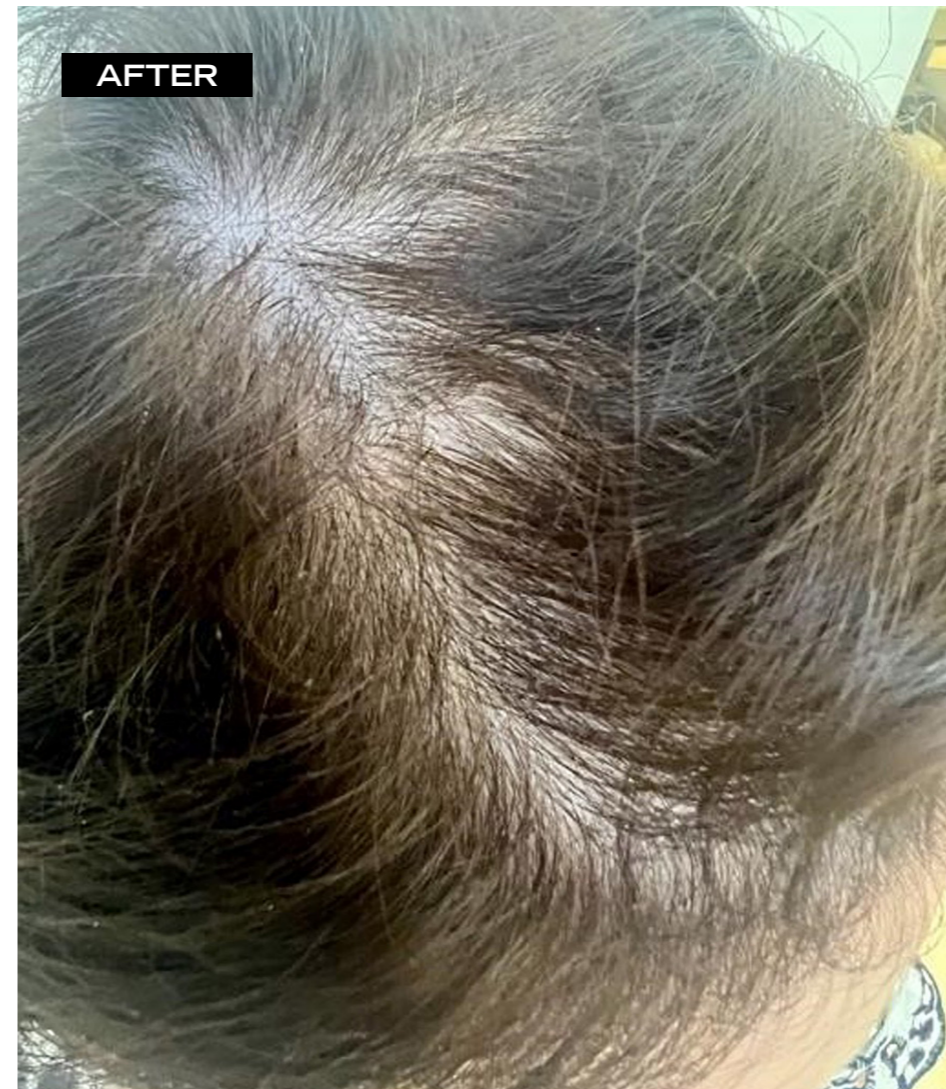
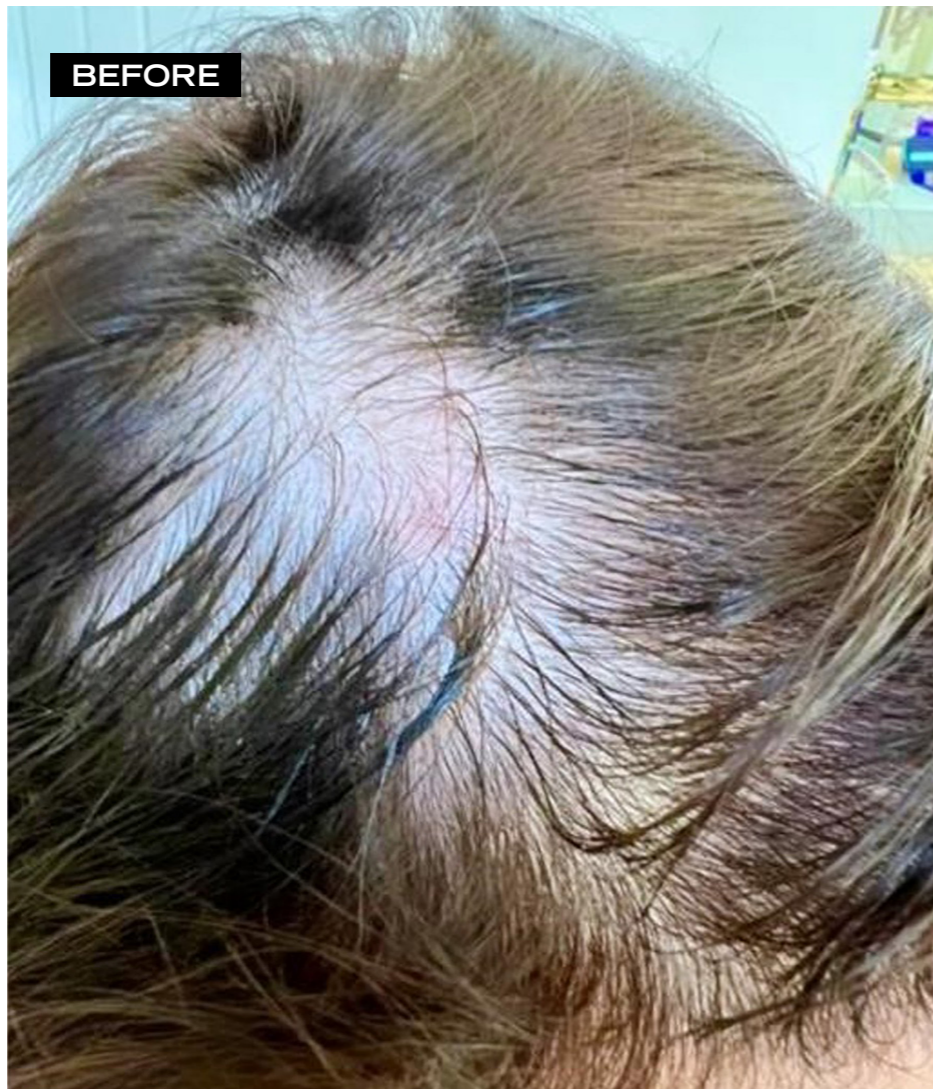

**PATIENT CONDITION:** Female alopecia.  
**TREATMENT:** INNO-EXOMO® EXO-SKIN applied with mesotherapy. 3 sessions, at 21-day intervals.  
**RESULT:** After the third session.

# INNO-EXOMA<sup>®</sup> EXO-SKIN

Exosome-like cosmetic regenerative complex

Elina Ribero, MD  
BRAZIL

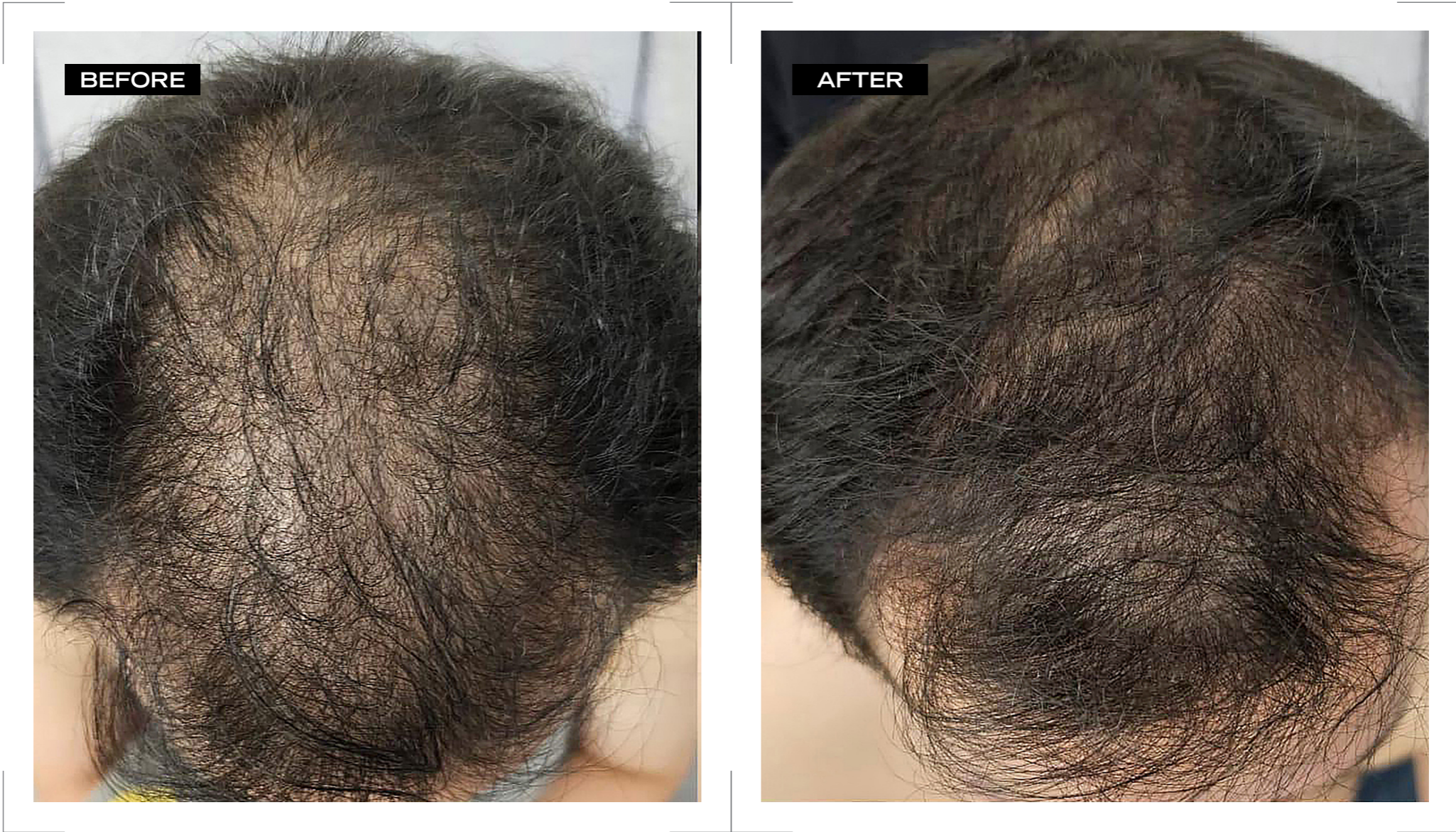

**PATIENT CONDITION:** Alopecia

**TREATMENT:** INNO-EXOMA<sup>®</sup> EXO-SKIN applied with Microneedling. 3 sessions with 21-day intervals.

**RESULT:** 35 days after the first session.

PORTUGAL

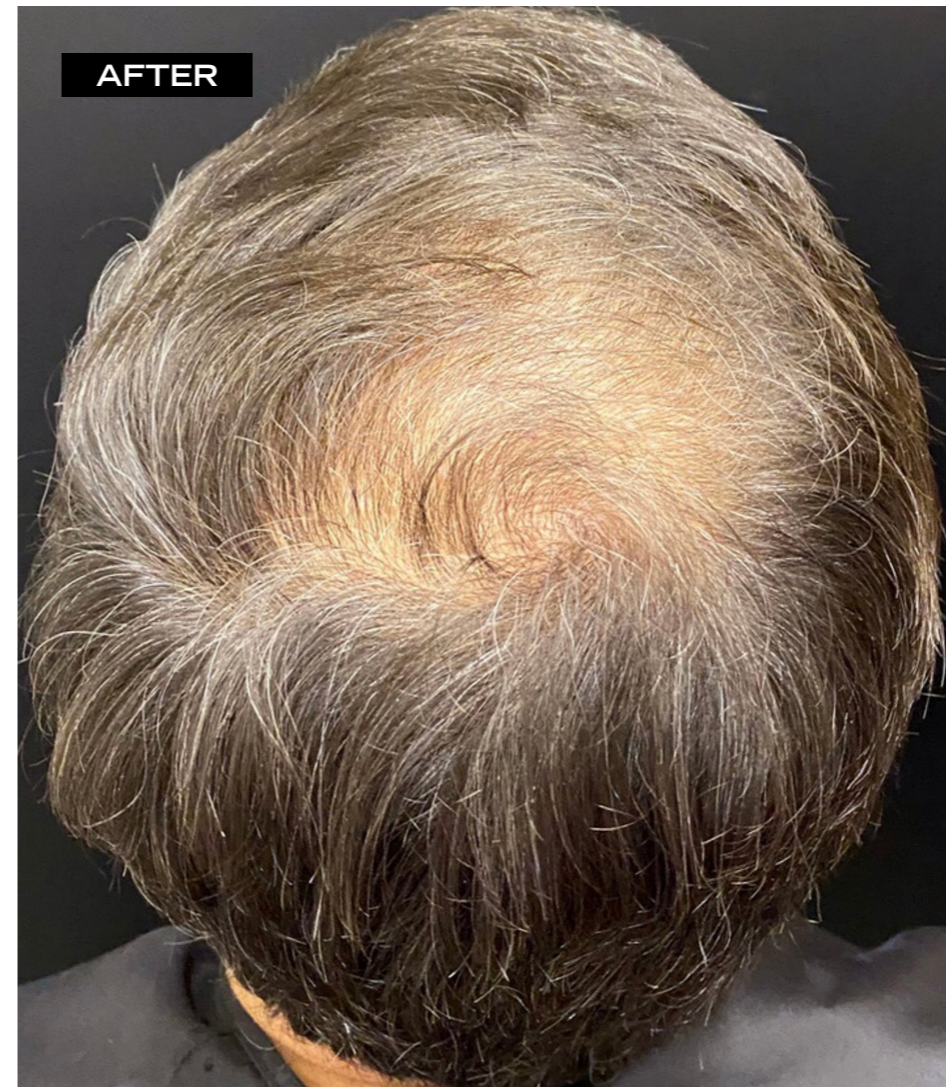
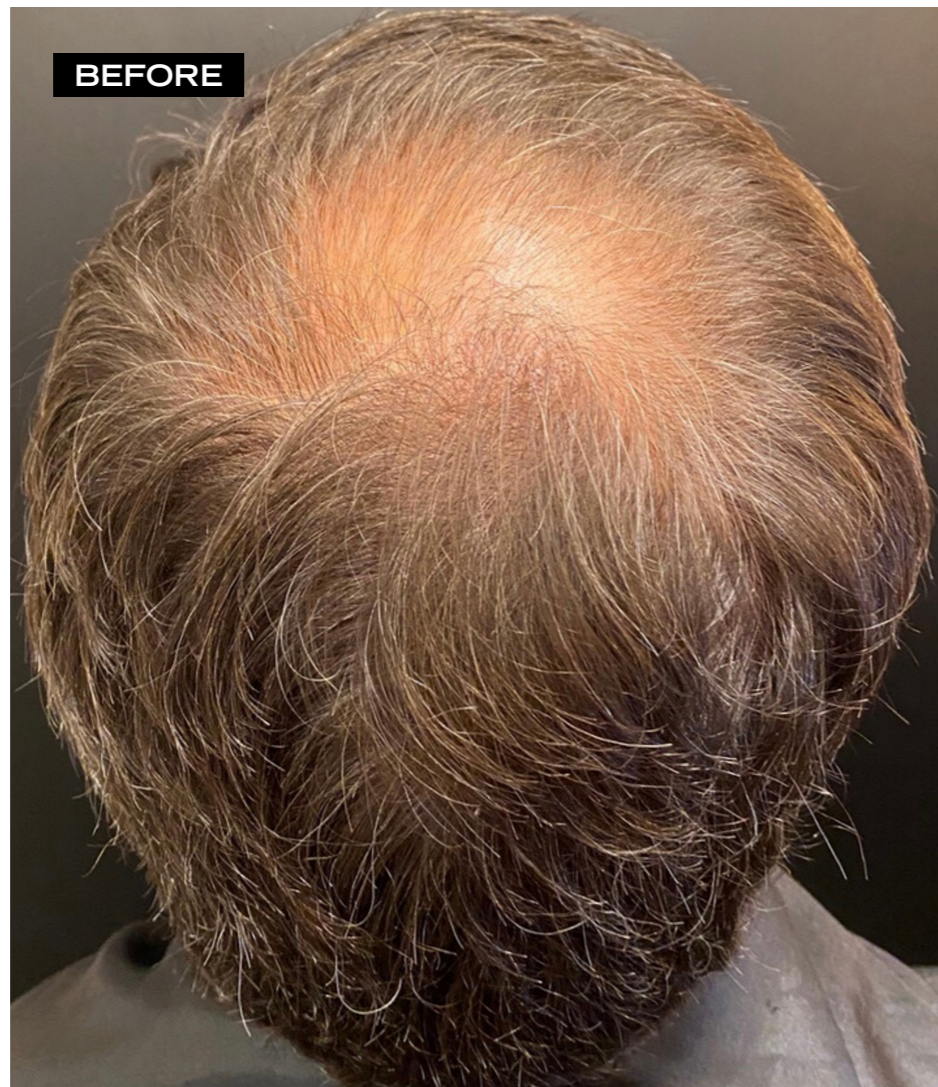
**PATIENT CONDITION:** Male alopecia.  
**TREATMENT:** INNO-EXOMO® EXO-SKIN applied with microneedling. 3 sessions, at 21-day intervals.  
**RESULT:** After the third session.

# INNO-EXOMA<sup>®</sup> EXO-SKIN

Exosome-like cosmetic regenerative complex

BRAZIL



**PATIENT CONDITION:** Male alopecia.

**TREATMENT:** INNO-EXOMO<sup>®</sup> EXO-SKIN applied with mesotherapy. 3 sessions, at 21-day intervals.

**RESULT:** After the third session.

BRAZIL

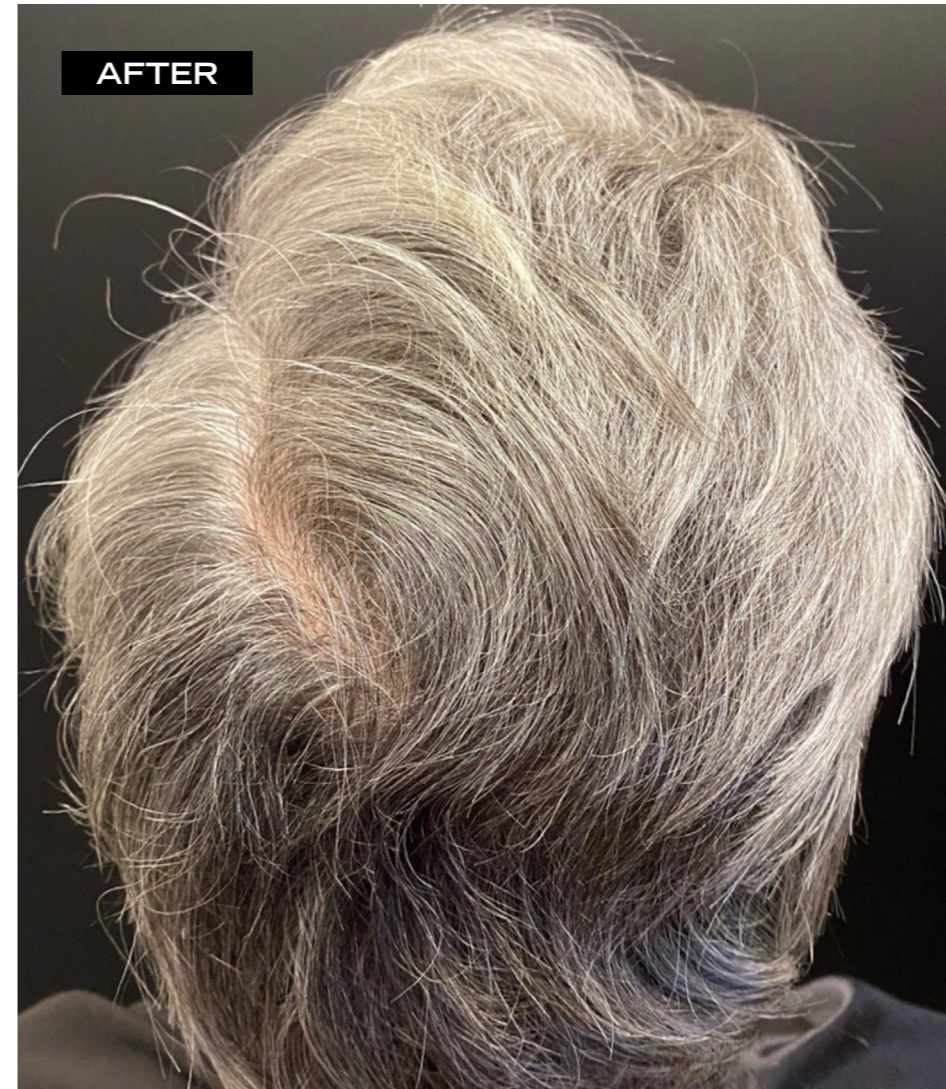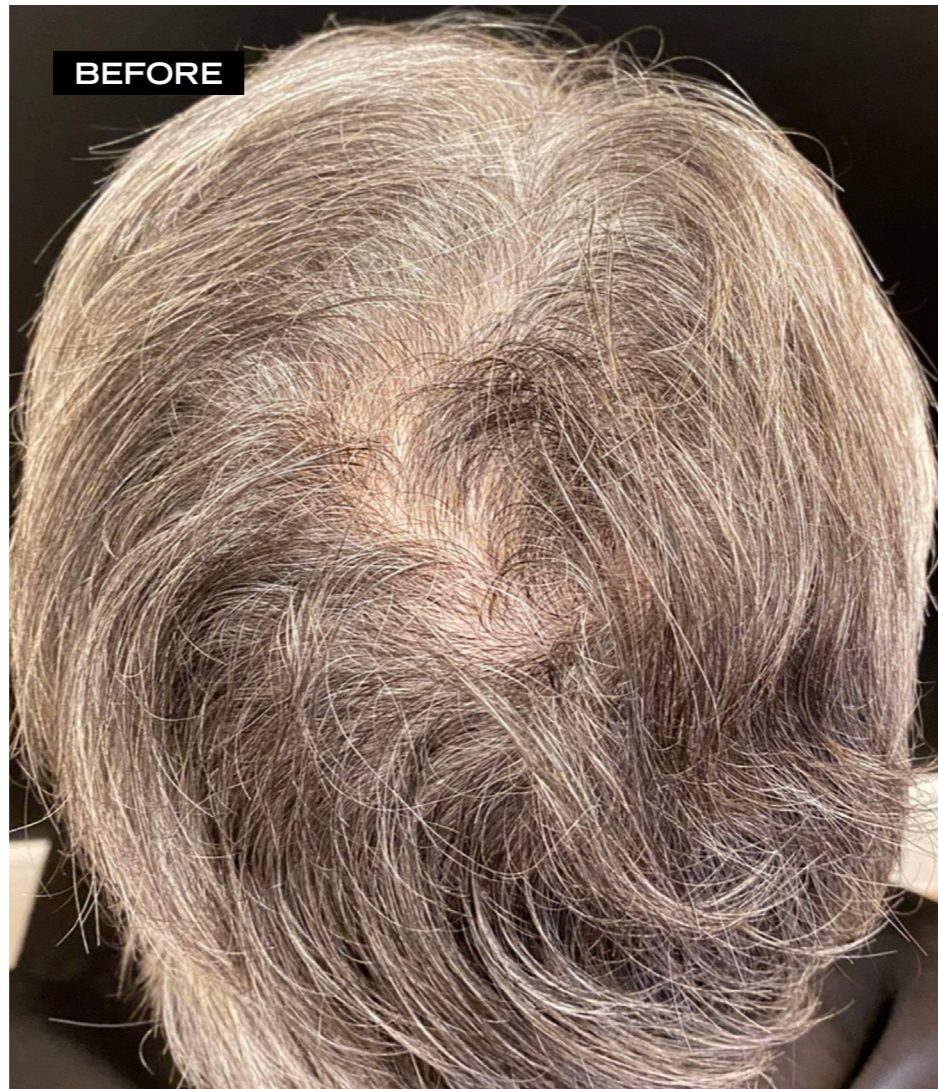


**PATIENT CONDITION:** Male hair loss.  
**TREATMENT:** INNO-EXOMO® EXO-SKIN applied with mesotherapy. 3 sessions, at 21-day intervals.  
**RESULT:** After the third session.

# INNO-EXOMA<sup>®</sup> EXO-SKIN

Exosome-like cosmetic regenerative complex

BRAZIL



**PATIENT CONDITION:** Male hair loss.

**TREATMENT:** INNO-EXOMO<sup>®</sup> EXO-SKIN applied with mesotherapy. 3 sessions, at 21-day intervals.

**RESULT:** After the third session.

BRAZIL



**PATIENT CONDITION:** Male hair loss.  
**TREATMENT:** INNO-EXOMO® EXO-SKIN applied with mesotherapy. 3 sessions, at 21-day intervals.  
**RESULT:** After the third session.